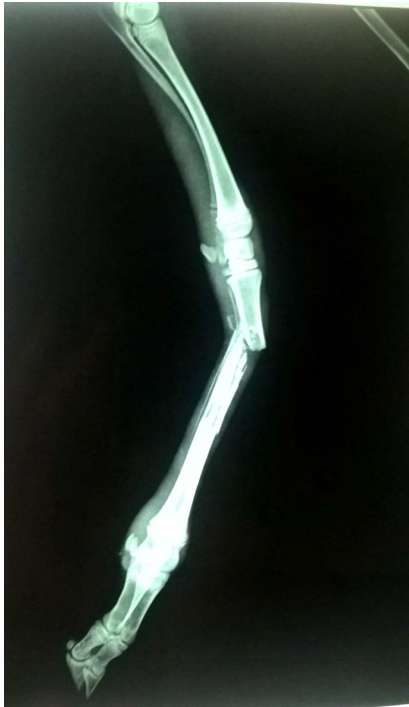


# Management of Metacarpal fracture in Chinkara (*Gazella bennettii*)

## Case History & Observations

A female Chinkara of around 6 month age was presented at Animal Rescue & Rehabilitation Center, Katraz Pune by forest department Pune with history of automobile



Radiograph of right fore limb (Fractured Metacarpal Bone)

accident with the chief complaint of limping with right fore limb. Clinical examination revealed no weight bearing lameness of right fore limb and on palpation crepitating sound was heard at metacarpal region. No swelling or wound was observed at the site of fracture. For confirmation of type of fracture radiological examination was carried out. Radiograph showed that a complete oblique compound fracture at the upper end of metacarpal shaft.

IUCN Red List:  
Least Concern

## Treatment & Discussion

As no open wound was observed repositioning of bone was carried out by counter traction method. External padded bamboo stick splint was applied for retention of apposed bone fragments which further fix with plaster of paris bandage cast. Immobilization of both fetlock and carpal joints of limb was achieved by these splints. Post operative animal was kept under observation in the rehabilitation center.

**Mammalia**  
(Class of Mammals)

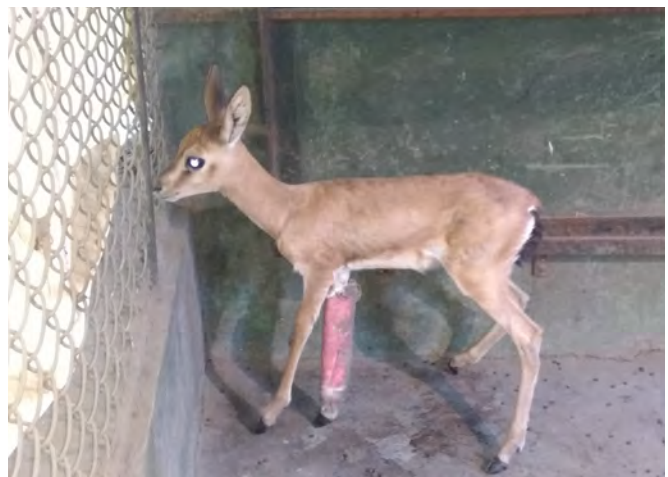**Artiodactyla**  
(Order of Even-toed ungulate)

**Bovidae**  
(Family of Cloven hoofed ruminants)

***Gazella bennettii***  
(Chinkara)

Species described by Sykes in 1831

Animal tolerated the bandage and bamboo splints. After one and half month post-operative radiological examination was carried out. It revealed that



External immobilization with bamboo stick splint & plaster of paris bandage Bone)



Animal after complete recovery

fracture bone was healed properly with callus formation.

Therefore, plaster of paris bandage and splints were removed. Animal started weight bearing on affected fore limb with normal limb movement without limping. The movement and running of animal was normal.

**Global Distribution:**  
Afghanistan, India,  
Iran, Islamic Republic  
of Pakistan

Management of fracture by surgical and non surgical means was documented by various researchers (Singh, G.R. *et al.*, 1982; Thiruthalinathan & Swaminathan, 1996). In the present study the treatment of fractured metacarpal bone was carried out with external application of bamboo stick splints and plaster of paris bandage. The treatment remedy of closed wound fracture and results was in accordance of earlier researcher (Ashwin Kumar, 2006) who successfully manages and treated metacarpal bone fracture in black buck by same method.

#### References

- Ashwini Kumar (2006).** Management of metacarpal fracture in a black buck *Antelope cervicapra*. *Zoos' Print Journal*, 21(2): 2174.
- Chhangani, A.K., P. Robbins & S.M. Mohanto (2010).** Major threats to the faunal diversity of Kumbhalgarh wildlife sanctuary in the Aravalli hills of Rajasthan. *Indian Forester*, Oct: 410-421.
- Dookia, S. (2009).** Conservation of Indian Gazelle or Chinkara through community support in Thar Desert of Rajasthan, India. *Project Technical Report, The Rufford Small Grant Foundation*.
- Newton, C.D. & D.M. Nunamaker (1985).** Management of open fractures cited in Text Book of Small animal Orthopaedics J.B. Lippincott Company, Philadelphia. 484p
- Singh, G.R., I.V. Mogha & B.M. Arora (1982).** Compound fracture of radius and ulna in deer (*Axis axis*) - A case report. *Indian Journal of Veterinary Surgery* 3(1): 38-41.
- Thiruthalinathan, R. & D. Swaminathan (1996).** Tibial fracture and its treatment in Sambar Deer (*Cervus unicornis*) - Case report. *Indian Journal of Veterinary Research* 5(2): 42-43.

**A.G. Dubey<sup>1</sup>, N.K. Nighot<sup>2</sup> & A.A. Sanghai<sup>3</sup>**

<sup>1-3</sup>Animal Rescue and Rehabilitation Centre, Katraz, Pune. Email: [1drankush.dubey@gmail.com](mailto:1drankush.dubey@gmail.com) (Corresponding author)

Citation: Dubey, A.G., N.K. Nighot & A.A. Sanghai (2017). Management of Metacarpal fracture in Chinkara (*Gazella banettii*). *Vet Brief* #6. In: *Zoo's Print* 32(11): 42:43.