

TREATMENT OF CERTAIN AILMENTS IN ZOO ANIMALS

Ashwani Kumar and V.K. Bhalla

Main article in Zoos' Print Journal 22(11):2900-2901; Manuscript 1636; ©Zoo Outreach Organisation; www.zoosprint.org

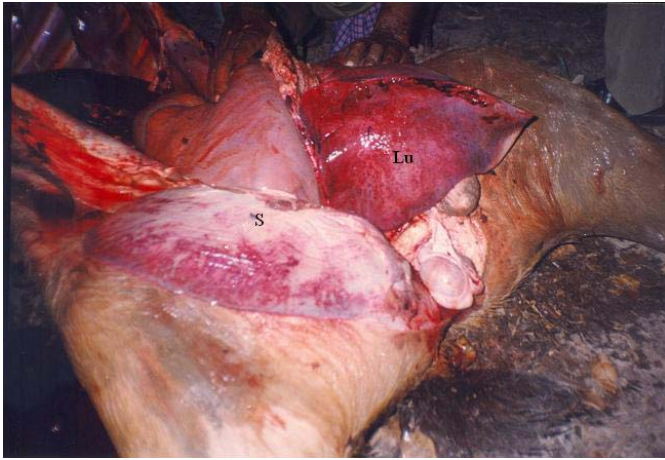


Image 1. Photograph showing haemorrhages on spleen (S) and Lungs (Lu)

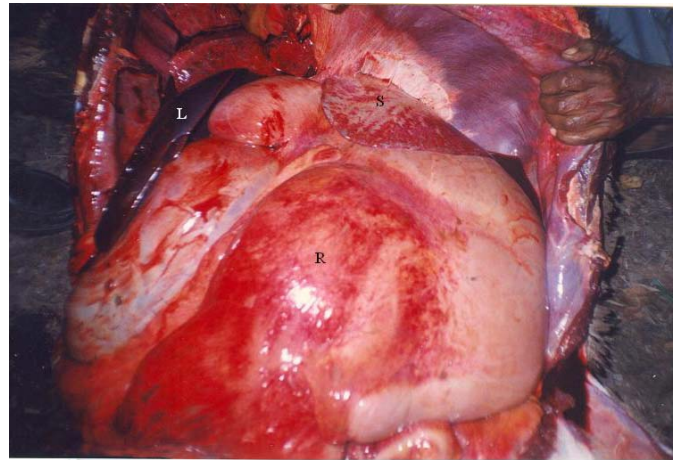


Image 2. Photograph showing haemorrhages on spleen (S) and rumen wall (R).

