

OCCURRENCE OF *BABESIA* INFECTION IN LEOPARD *PANTHERA PARDUS* AT NAGPUR

B.S. Baviskar, P.J. Gawande, D.K. Maske, A.K. Jayraw, S.S. Bawaskar and A.G. Bhandarkar

Main article in Zoos' Print Journal 22(6): 2736; Manuscript 1696; ©Zoo Outreach Organisation; www.zoosprint.org

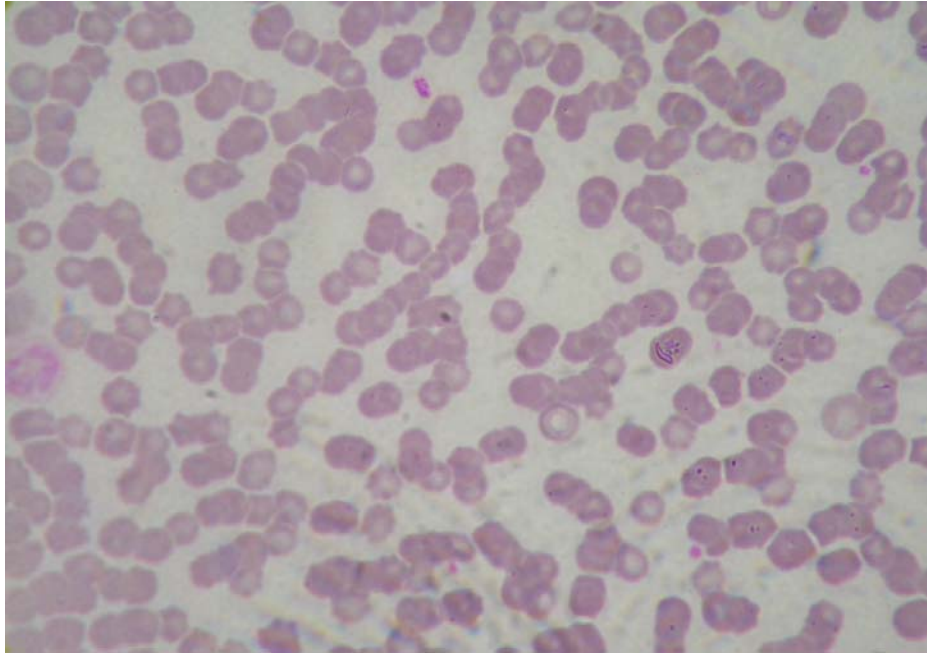


Image 1. Babesia sp. organisms in blood smear of a Leopard Panthera pardus

