

REHABILITATION OF AN INJURED INDIAN COBRA *NAJA NAJA*

T.K. Pattnaik, I. Nath, V.S.C. Bose, P. Parbathamma, J.K. Das and S.S. Lenka

Main article in Zoos' Print Journal 22(6): 2735-2736; Manuscript 1691; ©Zoo Outreach Organisation; www.zoosprint.org



Image 1. The depressed area in the mid-dorsum

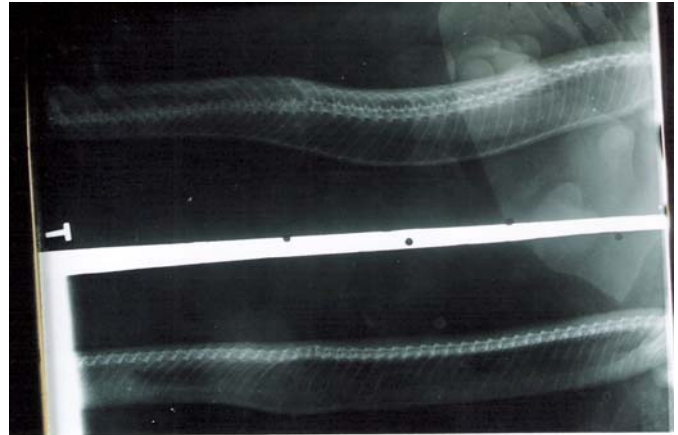


Image 2. Skiagram showing a fractured vertebrae



Image 3. Application of splint consisting of cut-syringe barrel



Image 4. Removal of splint

