


**PARASITIC INFECTIONS IN WILD HERBIVORES IN THE MAHENDRA CHOUDHURY ZOOLOGICAL PARK, CHHATBIR, PUNJAB**

**P. Singh, M.P. Gupta, L.D. Singla, S. Sharma, B.S. Sandhu and D.R. Sharma**

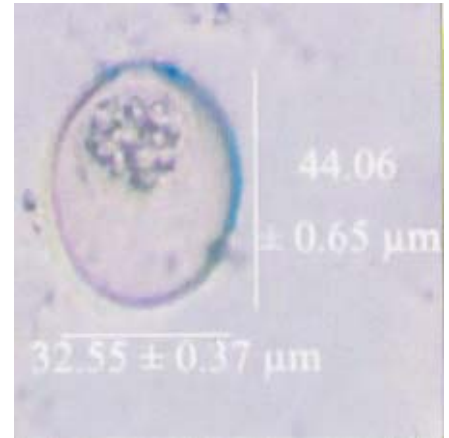
*Main article in Zoos' Print Journal 21(11): 2459-2461; Manuscript 1519; ©Zoo Outreach Organisation; www.zoosprint.org*



**Image 1. *Trichuris* spp. egg from Ladakhi goat (*Capra ibex*)**



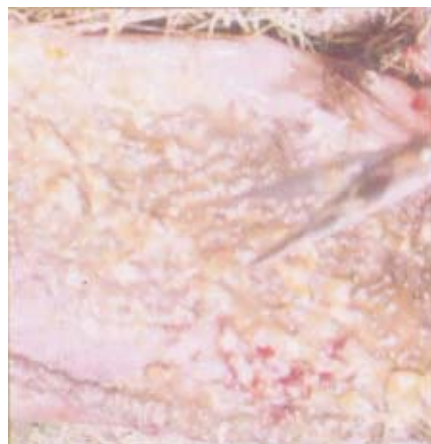**Image 2. *Trichuris* spp. egg from Chinkara (*Gazella gazella*)**



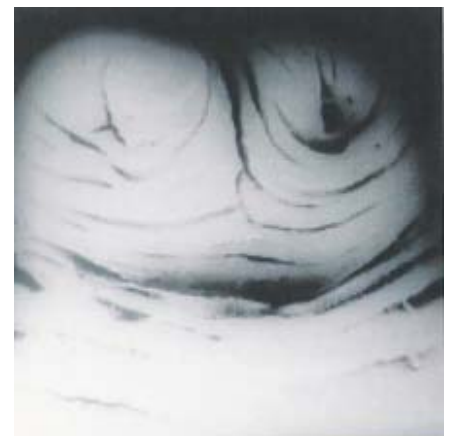**Image 3. *Eimeria* spp. oocyst from Chinkara (*Gazella gazella*)**



**Image 4. Stomach of Rhinoceros filled with tape worms**



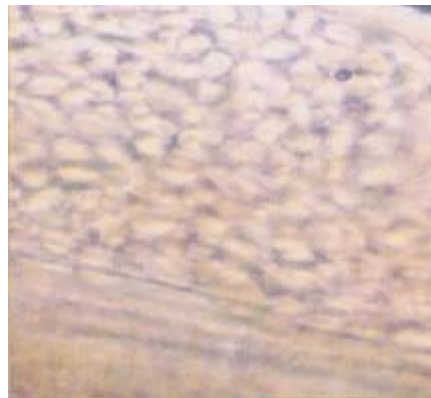
**Image 5. Tapeworms attached to the intestinal mucosa**



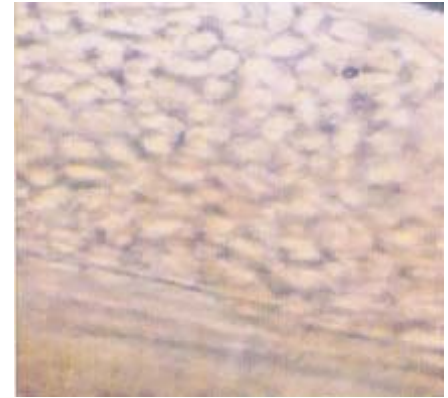
**Image 6. SEM anterior end *Anoplocephala magna* showing suckers**



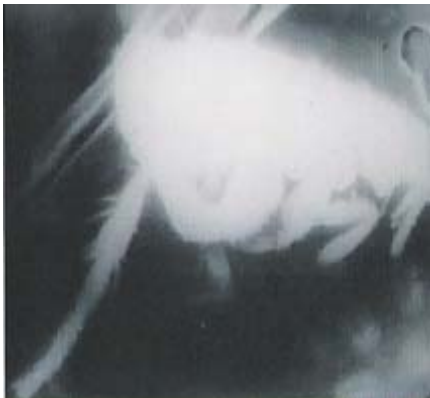**Image 7. Anterior end of Murshidia spp. worm showing leaf crown at the terminal**



**Image 8. Uterus of Murshidia spp. worm filled with eggs**



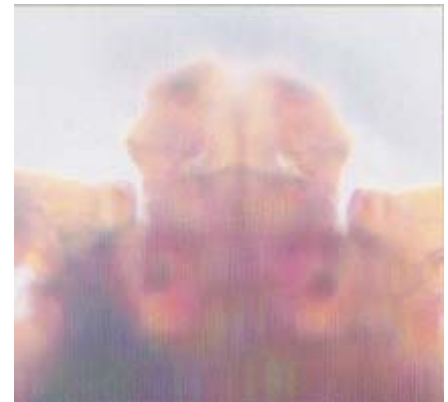**Image 9. SEM of lice Haematomyzus elephantis showing head and tubular mouth parts**



**Image 10. Ctenocephalides felis showing laterally flattened body and characteristic longest 3<sup>rd</sup> pair of legs**



**Image 11. Flea Ctenocephalidis spp. with both genal and pronotal combs from a hog deer**



**Image 12. Boophilus microplus mouth parts**

