

A CASE OF HISTIOCYTOMA IN A LEOPARD (*PANTHERA PARDUS*)

I. Nath, T.K. Pattnaik, N. Sahoo, V.S.C. Bose, H.K. Mohapatra and P.K. Roy

Main article in Zoos' Print Journal 21(6): 2302; Manuscript 1485c; © Zoo Outreach Organisation; www.zoosprint.org

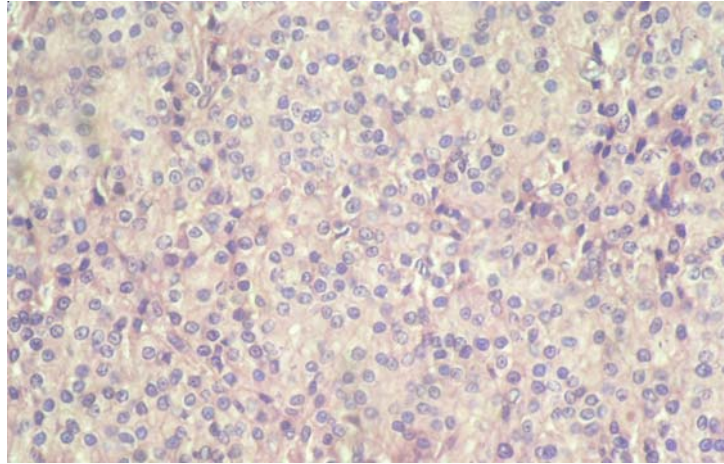


Image 1. Histiocytoma showing round to ovoid nuclei and indistinct compartmentalization (40x)

