

AN UNUSUAL CASE OF EPISTAXIS IN A WHITE TIGER (*PANTHERA TIGRIS*)

I. Nath, V.S.C. Bose, T.K. Pattanaik, S.K. Panda, R.K. Samantray and P.K. Roy

Main article in Zoos' Print Journal 20(11): 2079; Manuscript 1348; © Zoo Outreach Organisation; www.zoosprint.org

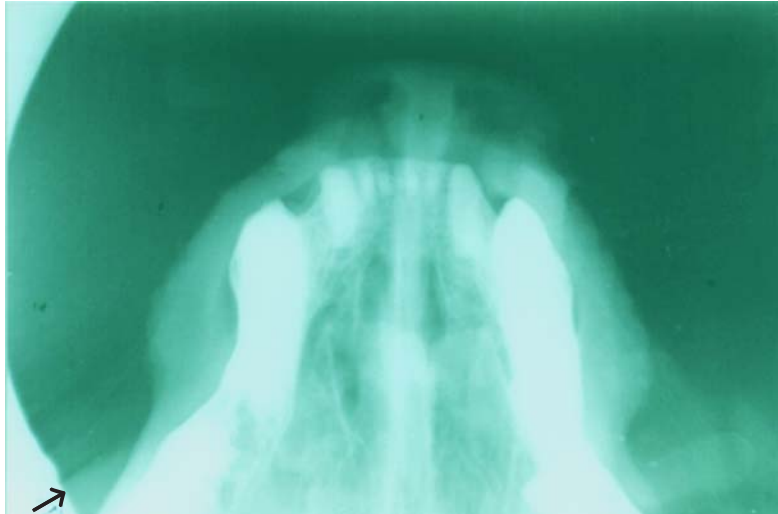


Image 1. Skiagram showing degenerative changes of right turbinates

