

MORPHOLOGY OF THE TONGUE OF INDIAN TIGER (*PANTHERA TIGRIS TIGRIS*)

M. Sarma, K.B. Dev Chouhaury, S.N. Kalita, K.K. Sarma and A. Chakraborty

Main article in Zoos' Print Journal 19(10): 1669; Manuscript 1181; © Zoo Outreach Organisation; www.zoosprint.org

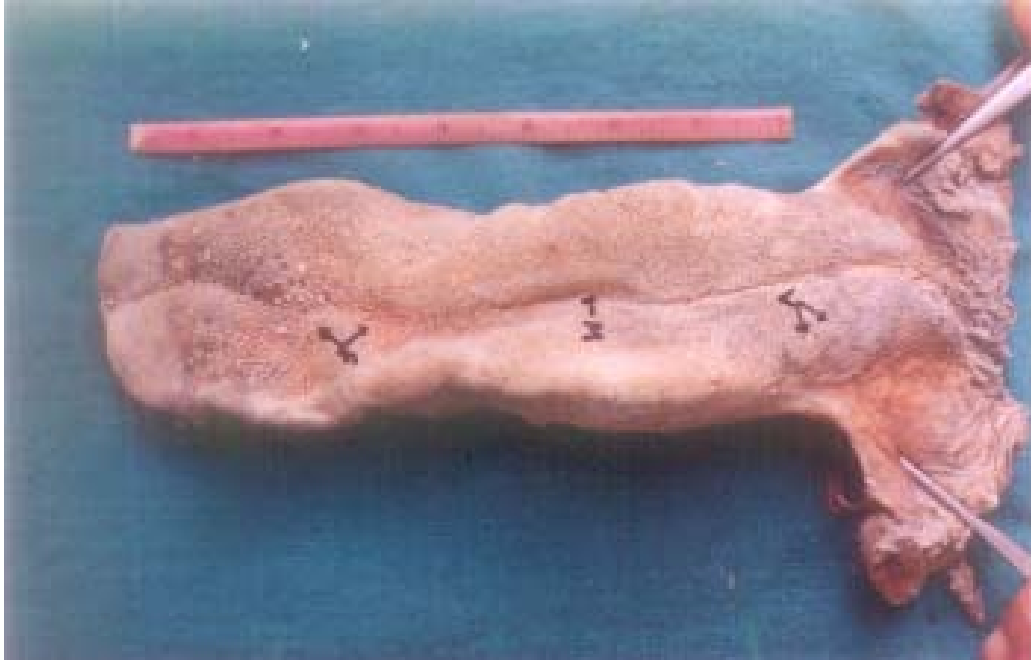


Image 1. Dorsum linguae of the tongue of white Bengal Tiger showing median groove (M), conical papillae (C), and circumvallate papillae (V)

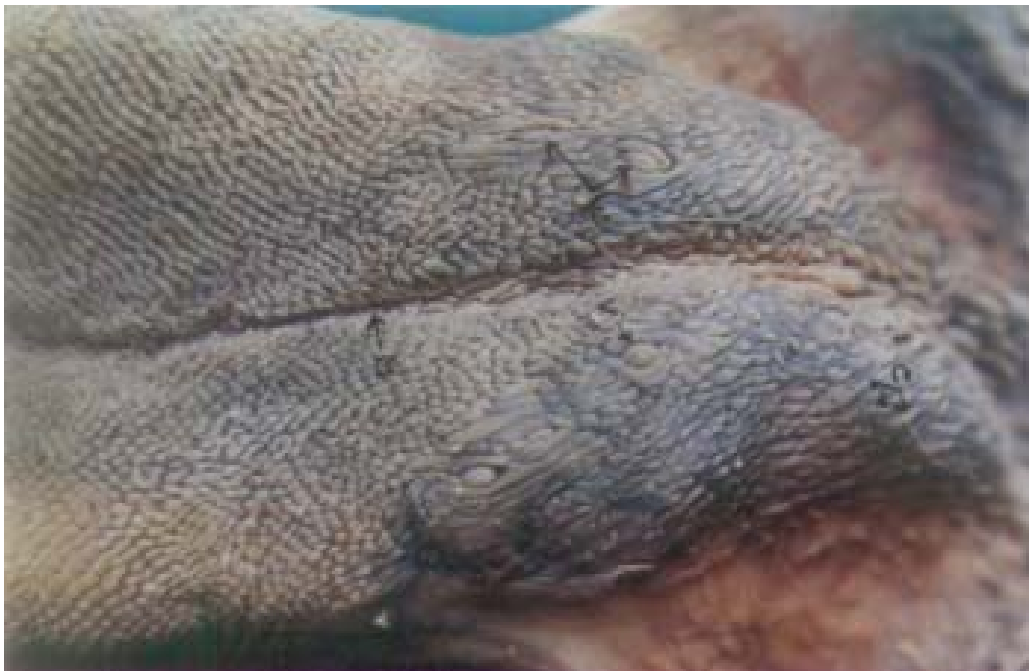

Image 2. Caudal half of the dorsum of tongue of white Bengal Tiger showing filiform papillae (F) at the root, median groove (M) and circumvallate papillae (V).

