

MACROMORPHOLOGY OF THE TONGUE OF AN ASIAN ELEPHANT (*ELEPHAS MAXIMUS*)

M. Sarma, M. Talukdar, K.B. Dev Choudhury and K.K. Sharma

Main article in Zoos' Print Journal 19(10): 1653; Manuscript 1065; © Zoo Outreach Organisation; www.zoosprint.org

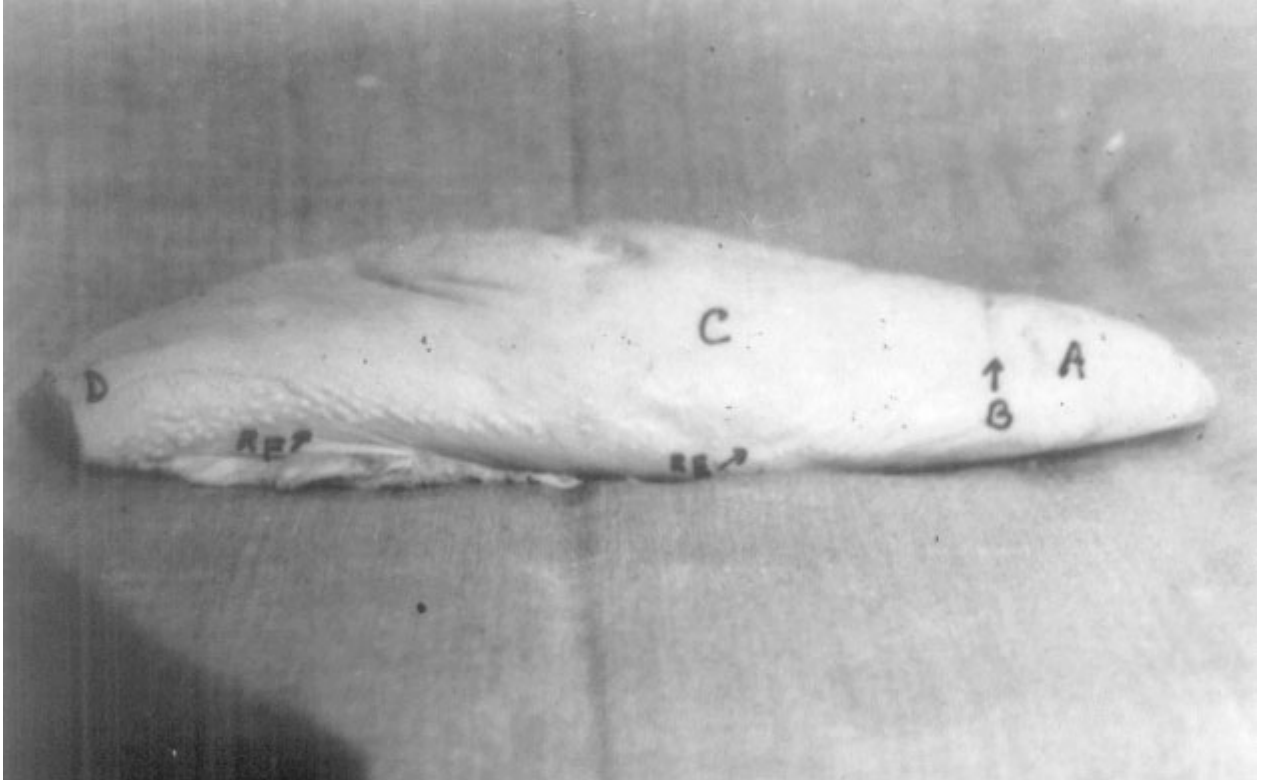


Image 1. Lateral view of the tongue of Asian Elephant showing tip (A), fossa linguae (B), torus linguae (C), root (D), fungiform papillae (E), and denticular papillae (F)

